

# Priapism due to chronic myelocytic leukemia turnitin

*by Syarif Bakri*

---

**Submission date:** 19-Apr-2022 01:26AM (UTC-0400)

**Submission ID:** 1814257158

**File name:** Priapism\_due\_to\_chronic\_myelocytic\_leukemia.pdf (1.35M)


**Word count:** 1607

**Character count:** 8893



Contents lists available at ScienceDirect

## Urology Case Reports

journal homepage: [www.elsevier.com/locate/eucr](http://www.elsevier.com/locate/eucr)

## Priapism due to chronic myelocytic leukemia

Syarif<sup>a,\*</sup>, Khoirul Kholis<sup>a</sup>, Muhammad Asykar Palinrungi<sup>a</sup>, Syakri Syahrir<sup>a</sup>, Abdul Azis<sup>a</sup>, Muhammad Arfan<sup>b</sup><sup>a</sup> Division of Urology, Department of Surgery, Faculty of Medicine, Hasanuddin University, Makassar, Indonesia<sup>b</sup> Department of Surgery, Faculty of Medicine, Hasanuddin University, Makassar, Indonesia

## ARTICLE INFO

## Keywords:

Priapism  
leukemia  
hematologic disorders  
bone marrow aspiration  
Winter procedure

## ABSTRACT

**2** Priapism is defined as a whole or partial penile erection that persists for more than 4 hours without stimulation. Hematologic disorders are a significant risk factor for ischemic priapism. Here, we report a case of priapism due to chronic myelocytic leukemia. This is rare considering that the epidemiology of priapism in hematologic malignancies includes only 1% of patients with chronic myelocytic leukemia. Priapism has a relatively high complication rate, and management generally focuses on prompt treatment. Hematologic screening should be performed to rule out the possibility of these disorders that could underlie priapism.

## 1. Introduction

Priapism is defined as a penile erection persisting for more than 4 hours without stimulation.<sup>1</sup> The three categories are ischemic, non-ischemic, and recurrent ischemic. Most cases are ischemic priapism, which is characterized by rigidity of the corpora cavernosa with little or no cavernous artery flow.<sup>1,2</sup>

Although sickle-cell anemia is the primary etiology of venous-occlusive priapism in the literature, various other causes range from urinary retention to insect bites. Hematologic disorders are also a significant risk factor for ischemic priapism. When priapism occurs in an oncological setting, evaluation and management of the predisposing condition should accompany penile-directed interventions.<sup>1</sup> Here, we report a case of priapism as a manifestation of chronic myeloid leukemia (CML).

## 2. Case presentation

A 27-year-old man presented with continuous penile erection for the previous 10 days. The complaint had appeared suddenly and had not been influenced by specific stimuli. This was the first episode of the condition. The main complaint was not accompanied by rashes, red spots, or bruises on the patient's body. The patient had no history of trauma but a history of spontaneous bleeding in the gums.

The patient had no systemic complaints such as fever, weakness,

headache, or abdominal pain. The urine was normal. No family history of the condition was known. On physical examination, the Kamofsky score was 70%. The vitality status was within normal limits. The localized status indicated anemic conjunctiva—the results of examinations of the neck, thorax, abdomen, and extremities were within normal limits. In the abdominal region, an enlarged spleen was found in Schufner 5. The penis was circumcised, erect, and hard, with dilated superficial veins, and with the external urethral meatus located in the center. Tenderness was present in the scrotal and perineal regions. The rectal examination results were within normal limits. The laboratory test results showed hemoglobin 9.5 g/dL, white blood cells (WBCs)  $620 \times 10^3/\text{mm}^3$ , platelets  $450 \times 10^3/\text{mm}^3$ , and uric acid 9.0 mg/dL.

We diagnosed the patient with ischemic priapism, suspected CML, and asymptomatic hyperuricemia. The patient was prepared for priapism surgery and treated with hydroxyurea 1,000 mg and allopurinol 300 mg to manage comorbidities. We performed the Winter procedure (Fig. 1); a venous catheter (16 Fr) was inserted into the corpus cavernosum through the glans penis at the 10 and 2 o'clock positions, with a brief flow of dark red blood. Venous catheter aspiration was performed to drain the blood slowly until penile detumescence. The procedure was ended by injecting epinephrine (1:100,000; 5 cc) into the right and left corpus cavernosa slowly over 20 minutes (Fig. 2).

Bone-marrow aspiration revealed chronic-phase CML. The final diagnosis was ischemic priapism, CML, and asymptomatic hyperuricemia. The patient received terbutaline sulfate 2.5 mg tid orally during the

\* Corresponding author. Division of Urology, Department of Surgery, Faculty of Medicine, Hasanuddin University, Jalan Perintis Kemerdekaan KM 11, Makassar, 90245, South Sulawesi, Makassar, Indonesia.

E-mail addresses: [syarifbakri@hotmail.com](mailto:syarifbakri@hotmail.com) (Syarif), [khoirulkholis@yahoo.com](mailto:khoirulkholis@yahoo.com) (K. Kholis), [apalinerungi@yahoo.com](mailto:apalinerungi@yahoo.com) (M.A. Palinrungi), [drsyakrisyahrir@gmail.com](mailto:drsyakrisyahrir@gmail.com) (S. Syahrir), [abdul.azis031@gmail.com](mailto:abdul.azis031@gmail.com) (A. Azis), [muhammadarfanmd@gmail.com](mailto:muhammadarfanmd@gmail.com) (M. Arfan).

<https://doi.org/10.1016/j.eucr.2021.101946>

Received 27 October 2021; Accepted 13 November 2021

Available online 16 November 2021

2214-4420/© 2021 The Authors.

Published by Elsevier Inc.

**4**

This is an open access article under the CC BY-NC-ND license

<http://creativecommons.org/licenses/by-nc-nd/4.0/>.

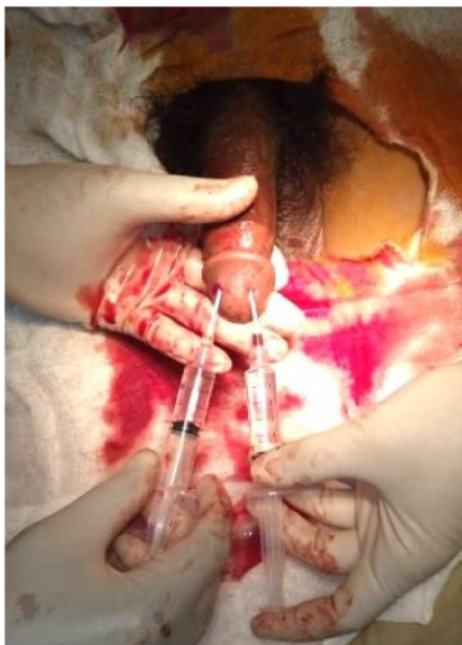

Fig. 1. Winter procedure for treating priapism.

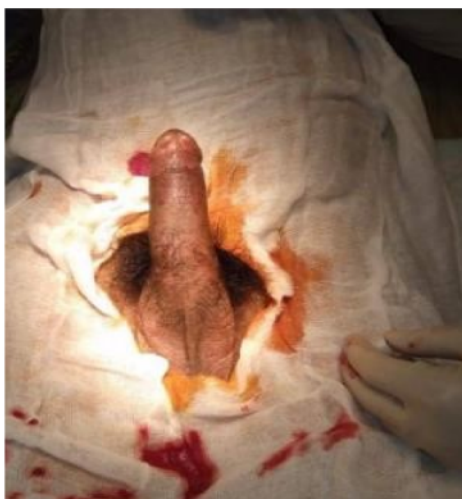

Fig. 2. The condition of the male genitalia after the Winter procedure.

postoperative treatment period. After being discharged, the patient returned for follow-up one month later. The patient complained of erectile dysfunction that had continued to the present.

### 3. Discussion

Priapism is a urological emergency, which must be treated as early as possible to prevent erectile dysfunction. Priapism is a rare condition, with an incidence of 0.7 cases per 100,000 person-years.<sup>3</sup> It is found in 1–5% of male patients with all types of leukemia. CML accounts for 50% of all cases of priapism due to leukemia. However, as a manifestation of CML itself, priapism is rare, present in only around 1–2% of cases.<sup>1</sup>

Patients with priapism usually present with complaints of an abnormally prolonged penile erection without stimulation. Important clinical questions include the duration of symptoms, medication or injection therapy used, erectile function before the episode of priapism, current medications, and history of underlying disorders known to predispose to priapism. In addition, the presence or absence of pain is important in determining ischemic or non-ischemic causes.<sup>2</sup>

In this case, the patient reported no history of drug use or trauma before the incident. The peripheral pulses of the penis should be palpated on physical examination to determine the presence or absence of high-flow arterial priapism. In ischemic priapism, the corpora cavernosa is usually tender, and not tender in non-ischemic priapism. A comprehensive history and physical examination are usually sufficient to determine the underlying etiology and subsequent treatment of this disease.<sup>2</sup>

Laboratory investigations such as complete blood counts are helpful in determining the etiology of priapism, especially those related to hematologic disorders. Patients with priapism due to CML may have high WBC levels at diagnosis, presenting as leukostasis or hyperviscosity syndrome.<sup>4</sup> If clinical evidence exists of hyperviscosity syndrome, leukapheresis can be performed.<sup>4</sup> In this case, the WBC value was 620,000/mm<sup>3</sup>, so the patient received 1,000 mg hydroxyurea therapy every 12 hours orally. The American Urological Association strongly recommends that systemic treatment of a disorder underlying priapism, such as CML, should not be undertaken as the sole treatment of ischemic priapism. Intracavernous treatment is required and should be given concurrently. Because ischemic priapism is a compartment syndrome, it requires directed primary treatment.<sup>2</sup> Systemic therapies commonly used in CML patients include cytoreductive treatment, such as high-dose hydroxycarbamide and a tyrosine kinase inhibitor, with or without the addition of leukapheresis. Therapeutic aspiration (with or without irrigation) or intra-cavernous sympathomimetic injection should be attempted initially to treat priapism.<sup>1,4</sup> In this case, the patient was managed using the Winter procedure.

In addition, patients can be given drugs, such as epinephrine or terbutaline, to overcome vasodilation of the penile vessels and stop the erection.<sup>5</sup> The prognosis of priapism depends on the duration of symptoms, underlying pathology, and patient's age. The longer the duration of the symptoms, the worse the outcome. Long-term risk of erectile dysfunction is also common, despite optimal treatment.<sup>2</sup> In this case, the patient had erectile dysfunction that might have been caused by the delay in managing the condition.

### 4. Conclusion

Priapism is a rare condition, with high complication rates, whose management generally focuses on prompt treatment. After taking a history and physical examination in a patient with priapism, hematologic screening should be performed to rule out the possibility of undiagnosed CML or other underlying hematologic disorders.

### Consent

Written informed consent for publication of their clinical details and/or clinical images was obtained from the patients.

### Funding

This research did not receive any specific grant from funding agencies in the public, commercial, or not-for-profit sectors.

### Declaration of competing interest

None.

### Acknowledgement

We would like to express our appreciation to Muhammad Faruk M.D for his contribution in editing and reviewing this case report.

### References

1. Nerli RB, Magdum PV, Hiremath SC, et al. Priapism – a rare presentation in chronic myeloid leukemia: case report. *Urol Case Reports*. 2016;4:8–10. <https://doi.org/10.1016/j.eucr.2015.08.005>.
2. Anele UA, Le BV, Resar LMS, Burnett AL. How I treat priapism. *Blood*. 2015;125:3551–3558. <https://doi.org/10.1182/blood-2014-09-551887>.
3. Zhong W, Jina H, Rathore P, et al. A case report of priapism with unusual presentation and clinical course. *Urol Case Reports*. 2017;12:70–72. <https://doi.org/10.1016/j.eucr.2017.03.009>.
4. Minckler MR, Conser E, Figueroa JJ, Scott AJ, Gaither J, Amini R. The semantic of priapism and the first sign of chronic myeloid leukemia. *Case Rep Emerg Med*. 2017;1:3. <https://doi.org/10.1155/2017/2656203>, 2017.
5. Qu M, Lu X, Wang L, Liu Z, Sun Y, Gao X. Priapism secondary to chronic myeloid leukemia treated by a surgical cavernosa–corpus spongiosum shunt: case report. *Asian J Urol*. 2019;6:373–376. <https://doi.org/10.1016/j.ajur.2018.12.004>.

# Priapism due to chronic myelocytic leukemia turnout

## ORIGINALITY REPORT

5%

SIMILARITY INDEX

6%

INTERNET SOURCES

2%

PUBLICATIONS

0%

STUDENT PAPERS

## PRIMARY SOURCES

1

[academictree.org](https://www.academictree.org)

Internet Source

2%

2

[tau.amegroups.com](https://tau.amegroups.com)

Internet Source

1%

3

[onlinelibrary.wiley.com](https://onlinelibrary.wiley.com)

Internet Source

1%

4

Haviv Muris Saputra, Yudhistira Pradnyan Kloping, Johan Renaldo, Lukman Hakim. "An earphone wire inside the urinary bladder: A case report and comprehensive literature review of genitourinary polyembolokoilamania", Radiology Case Reports, 2022

Publication

1%

Exclude quotes Off

Exclude matches < 15 words

Exclude bibliography Off